



Image: A. Zangrilli, Wikimedia Commons

TREATMENT OF PAEDIATRIC OBSTRUCTIVE SLEEP APNOEA WITH ORAL APPLIANCES

Maria Pia Villa

Department of Mental Health and Sense Organs, “La Sapienza” University, II Faculty, Medicine, Rome, Italy

Obstructive sleep apnoea syndrome (OSAS) is a disorder of breathing during sleep characterised by prolonged partial airway obstruction and/or intermittent complete obstruction (obstructive apnoea) that interrupts normal ventilation during sleep and disrupts normal sleep pattern, affecting about 2–3% of children [1, 2].

Although adenotonsillar hypertrophy remains the main causative factors inducing OSAS in children, other conditions involving a reduction of the calibre of the upper airways, such as craniofacial dysmorphism, obesity, hypotonic neuromuscular diseases, can be aetiologic factors [3, 4]. Orthodontic and craniofacial abnormalities are commonly ignored, despite many children with OSA displaying mild craniofacial morphometric anomalies [5–8]. Figure 1 shows the typical and common phenotype of a child with

OSA, displaying a long face and narrow palate. A narrow upper airway accompanied by maxillary constriction and mandibular retrusion is commonly reported [4, 6, 8, 9] with a skeletal conformation showing hyperdivergent skeletal growth pattern. All these factors induce an increase of the craniomandibular, intermaxillary, goniac and mandibular angles [10]. Similarly to the major congenital craniofacial anomalies, a mandibular retroposition is associated with posterior displacement of the tongue base, which increase the upper airway narrowing and leads to a high-arched (ogival) palate (fig. 2) [10, 11]. It is still debated whether these morphological features are genetically determined or influenced by the early onset of habitual snoring, and their reversibility by adenotonsillectomy (AT) has yet to be determined [10].

Correspondence

M.P. Villa
Pediatric Clinic
Sant’Andrea Hospital
Via Grottarossa 1035/1039 - 00189
Rome
Italy

E-mail

mariapia.villa@uniroma1.it

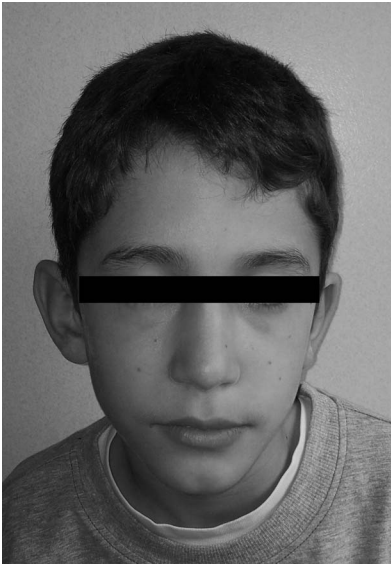

FIGURE 1. An example of a common phenotype of a child with obstructive sleep apnoea: long face, facial asymmetry and narrow palate.

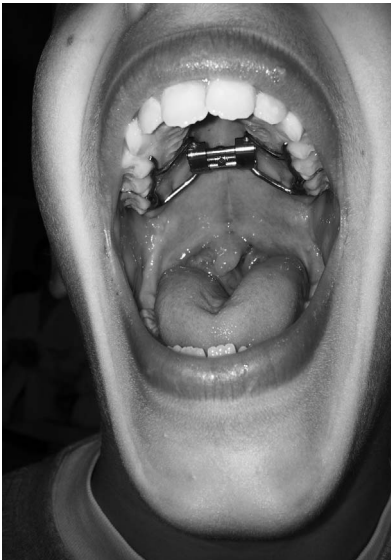


FIGURE 2. An example of rapid maxillary expansion device applied to a narrow palate and dental crowding.

For all these reasons, orthodontic treatment based on oral appliances is a potential treatment for paediatric OSAS [12, 13], because it acts by enlarging the upper airway and/or by decreasing upper airway collapsibility and enhancing upper airway muscle tone [13].

ORTHODONTIC TREATMENT IN ADULTS WITH OSA: LITERATURE DATA

Similar to children, adults with OSA may be candidates for orthodontic treatments. Although the current standard treatment for adults with OSAS consists of nocturnal application of continuous positive airway pressure (CPAP) *via* a nasal mask, LIM *et al.* [14] in 2005 suggested that it would appear appropriate to recommend oral appliances to patients with mild symptomatic OSA, and to those who are unwilling or unable to tolerate CPAP therapy. Removable oral appliances might be an alternative treatment options mostly for adults with OSA and mandibular retrusion. The most effective appliance used is the mandibular advancement splint (MAS) which reduces upper airway collapsibility during sleep, and increases the total airway volume, acting mostly by an increase in the volume of the velopharynx, an increase in the lower anterior facial height, a reduction in the distance between the hyoid and posterior nasal spine and anterior movement of the tongue base muscles [12, 15, 16]. All these data demonstrated that oral appliances have improved upper airway and craniofacial abnormalities in adults with OSA. They appear to be a valid alternative therapy to adult patients with mild symptomatic OSAS and to those subjects who are not compliant with CPAP therapy [14].

ORTHODONTIC TREATMENT IN PAEDIATRIC OSA: LITERATURE DATA

The Italian National Guidelines Consensus Conference for paediatric adenotonsillectomy have recommended an orthodontic assessment in all children with SDB and malocclusions or craniofacial anomalies [17]. This is despite the fact only limited

data are available about short- and long-term efficacy of orthodontic treatment in paediatric OSA and there is insufficient evidence to state that oral appliances or functional orthopaedic appliances are effective in the treatment of OSAS in children [18, 19].

The rapid maxillary expansion (RME) is the most common dento-facial orthopaedic procedure used in young patients to treat maxillary transverse deficiencies, starting from 4 yrs of age. Children with mild craniofacial anomalies usually display unilateral or bilateral posterior cross-bite and anterior dental crowding (fig. 2). The distance between the lateral walls of the nasal cavity and the nasal septum is reduced, leading to increased nasal respiratory difficulties and increase of nasal resistance [20, 21]. RME act to increase the transverse dimensions of the maxilla, which, in turn, widens the nasal cavity. RME treatment induces widening of the maxilla, corrects posterior crossbites, improves maxillary and mandibular dental arch coordination and increases the arch perimeter [22]. RME is performed using a device with an expansion screw joined to the bands on the first premolars and first molars, and it is periodically activated, opening the mid-palatal suture (fig. 2). It is usually removed after ~6–12 months. Patients undergo monthly follow-up assessments until the orthodontic treatment ends [23].

A study reported data about short-term effect of an oral jaw positioning appliance in a sample of 32 school-aged children with OSAS and malocclusions, demonstrating a significant reduction in the apnoea-hypopnoea index and in diurnal symptoms after 6 months of therapy [24], while another study demonstrated for the first time that RME may yield positive long-term effects in children with OSA [25]. In particular, that study reported the effect of RME applied for 6–12 months, in a relatively small sample of non-obese children suffering from OSAS. All children had not adenotonsillar hypertrophy. 4 months after the end of the

orthodontic treatment, all children had normal anterior rhinometry and a resolution of OSA, with an apnoea-hypopnoea index of $<1 \text{ event} \cdot \text{h}^{-1}$ [25]. A similar result was obtained after one year of treatment with RME in 16 preschool and school aged non-obese children with OSAS and dental malocclusions: at the initial evaluation children presented a high, narrow, ogival palate associated with malocclusions such as deep bite, retrusive bite or crossbite; they also had a mild or severe form of adenotonsillar hypertrophy and parents refused AT [20]. The RME was removed after 12 months and clinical symptoms of SDB improved as long as the apnoea-hypopnoea index dropped significantly in most of them. The changes in the apnoea-hypopnoea index varied according to the type of malocclusion, dropping to a greater extent in subjects with deep, retrusive bite than in those with crossbite [20]. In that study, therapeutic success was achieved despite the presence of

adenotonsillar hypertrophy and by starting treatment early when the bone is still extremely plastic and its growth rate is maximum [20]. The effects of this treatment persisted even 2 yrs after the end of the RME application as demonstrated by a long-term study on the same population of children, expressed by the stable decrease of apnoea-hypopnoea index, the increase of mean overnight oxygen saturation and the persistent improvement of clinical symptoms of obstructive sleep respiratory disorders [26]. Finally, a recent randomised study showed preliminary results about the effect of orthodontic treatments by means of RME applied before AT compared with the effect of RME applied after AT, in children with OSA [27]. The authors reported no significant differences between the two different approaches, although children treated firstly with RME showed a significant improvement of OSA, compared with baseline [27]. That study supports the idea that

a multi-therapeutic approach to OSA is needed and that the best results of RME are achieved when orthodontic therapy is started early.

CONCLUSION

Notwithstanding, AT is the primary therapy for OSA in children, the efficacy and the resolution of OSAS after adeno-tonsillectomy remains uncertain, depending on the severity and on the association with other co-morbidities [28]. Since residual disease is reported in a large proportion of children after adeno-tonsillectomy [28], and children with OSA display a complex phenotype (mild or major craniofacial anomalies and/or comorbid obesity and/or adeno-tonsillar enlargement), a multi-therapeutic approach to paediatric OSAS and a defined timing of therapy are required with a greater degree of collaboration between sleep medicine, ear, nose and

TABLE 1. Multi-therapeutic stepwise approach to the phenotypes of pediatric obstructive sleep apnoea

Congenital phenotype (retrognathia and micrognathia, Pierre Robin sequence)	1. Maxillo-facial surgery mostly consisting in early mandibular advancement
	2. Orthodontic treatment (depending on the severity of OSA: after surgery or replacing surgery)
	3. Nasal CPAP (before surgery, or after surgery depending on residual disease)
	4. Medical therapy (topic and systemic anti-inflammatory drugs)
	5. Oropharyngeal exercise therapy if there is persistence of oral breathing after steps 1-3
Common phenotype (long face, narrow palate, minor malocclusions, adenotonsillar hypertrophy)	1. Adenotonsillectomy
	2. Orthodontic treatment by oral appliances (depending on the severity of OSA: after surgery or replacing surgery)
	3. Nasal CPAP (after surgery depending on the presence of residual disease)
	4. Medical therapy (topic and systemic anti-inflammatory drugs)
	5. Oropharyngeal exercise therapy if there is persistence of oral breathing after step 1 and 2 and 3
Adult type (obesity, midface hypoplasia and short neck)	1. Hypocaloric diet
	2. Nasal CPAP or BiPAP depending on the compliance of child
	3. Orthodontic treatments by oral appliance of malocclusions and or narrow palate
	4. Medical therapy (topical and systemic anti-inflammatory drugs)
	5. Oropharyngeal exercise therapy if there is persistence of oral breathing after steps 1-3

OSA: obstructive sleep apnoea; CPAP: continuous positive airway pressure; BiPAP: bilevel positive airway pressure; AHI: apnoea-hypopnoea index

throat specialists, and orthodontists [28, 29]. A proposed model of therapy for paediatric OSA is described in table 1, depending on the prevalent phenotype expressed by the child: congenital type is represented by the phenotype starting from infancy and mostly related to the Pierre Robin sequence, with retrognathia and micrognathia; the common type is represented by long face, narrow palate and hypotonic lips and nose cartilage; and the adult type is characterised by obesity, a short neck and midface hypoplasia. Each phenotype may be associated with several degree of enlargement of adenoid and tonsils, which mostly occurs in the common type.

In conclusion, orthodontic therapy may be considered, regardless of the severity of OSA, as potentially making a valid contributions to treatment [30]. The results of the studies described suggest that that an early approach with oral appliances may permanently modify nasal breathing and respiration and changes of natural history of paediatric OSAS. These data about early orthodontic therapy suggest that this is an additional option for paediatricians treating children with OSA [22].

REFERENCES

- Montgomery-Downs HE, Crabtree VM, Gozal D. Cognition, sleep and respiration in at risk children treated for obstructive sleep apnoea. *Eur Respir J* 2005; 25: 336–342.
- Lumeng JC, Chervin RD. Epidemiology of pediatric obstructive sleep apnea. *Proc Am Thorac Soc* 2008; 5: 242–252.
- Marcus CL, McColley SA, Carroll JL, et al. Upper airway collapsibility in children with obstructive sleep apnea syndrome. *J Appl Physiol* 1994; 77: 918–924.
- Arens R, Marcus CL. Pathophysiology of upper airway obstruction: a developmental perspective. *Sleep* 2004; 27: 997–1019.
- Agren K, Nordlander B, Linder-Aronsson S, et al. Children with nocturnal upper airway obstruction: postoperative orthodontic and respiratory improvement. *Acta Otolaryngol* 1998; 118: 581–587.
- Kawashima S, Peltomaki T, Sakata H, et al. Craniofacial morphology in preschool children with sleep-related breathing disorder and hypertrophy of tonsils. *Acta Paediatr* 2002; 91: 71–77.
- Kulnis R, Nelson S, Strohl K, et al. Cephalometric assessment of snoring and nonsnoring children. *Chest* 2000; 118: 596–603.
- Shintani T, Asakura K, Kataura A. Evaluation of the role of adenotonsillar hypertrophy and facial morphology in children with obstructive sleep apnea. *ORL J Otorhinolaryngol Relat Spec* 1997; 59: 286–291.
- Guilleminault C, Li KK, Khramtsov A, et al. Sleep disordered breathing: surgical outcomes in prepubertal children. *Laryngoscope* 2004; 114: 132–137.
- Zucconi M, Caprioglio A, Calori G, et al. Craniofacial modifications in children with habitual snoring and obstructive sleep apnoea: a case-control study. *Eur Respir J* 1999; 13: 411–417.
- Jamieson A, Guilleminault C, Partinen M, et al. Obstructive sleep apneic patients have craniomandibular abnormalities. *Sleep* 1986; 9: 469–477.
- Chan AS, Sutherland K, Schwab RJ, et al. The effect of mandibular advancement on upper airway structure in obstructive sleep apnoea. *Thorax* 2010; 65: 726–732.
- Ferguson KA, Cartwright R, Rogers R, et al. Oral appliances for snoring and obstructive sleep apnea: a review. *Sleep* 2006; 29: 244–262.
- Lim J, Lasserson TJ, Fleetham J, et al. Oral appliances for obstructive sleep apnoea. *Cochrane Database Syst Rev* 2006; 25: CD004435.
- Bloch KE. Alternatives to CPAP in the treatment of the obstructive sleep apnea syndrome. *Swiss Med Wkly* 2006; 136: 261–267.
- Ng AT, Gotsopoulos H, Qian J, et al. Effect of oral appliance therapy on upper airway collapsibility in obstructive sleep apnea. *Am J Respir Crit Care Med* 2003; 168: 238–241.
- Sistema nazionale le linee guida appropriatezza e sicurezza degli interventi di tonsillectomia e/o adenoidectomia. [Appropriateness and safety of tonsillectomy and/or adenoidectomy]. www.apel-pediatri.it/Linee%20guida/Linee%20Guida%20adenotonsillectomia%20mar%202006.pdf.
- Villa MP, Miano S, Rizzoli A. Mandibular advancement devices are an alternative and valid treatment for pediatric obstructive sleep apnea syndrome. *Sleep Breath* 2011; [Epub ahead of print DOI: 10.1007/s11325-011-0595-9].
- Carvalho FR, Lentini-Oliveira D, Machado MA, et al. Oral appliances and functional orthopaedic appliances for obstructive sleep apnoea in children. *Cochrane Database Syst Rev* 2007; 18: CD005520.
- Monini S, Malagola C, Villa MP, et al. Rapid maxillary expansion for the treatment of nasal obstruction in children younger than 12 years. *Arch Otolaryngol Head Neck Surg* 2009; 135: 22–27.
- Ramires T, Alcântara Maia R, et al. Nasal cavity changes and the respiratory standard after maxillary expansion. *Rev Bras Otorrinolaringol* 2008; 74: 763–769.
- Cistulli PA, Palmisano RG, Poole MD. Treatment of obstructive sleep apnea syndrome by rapid maxillary expansion. *Sleep* 1998; 21: 831–835.
- Villa MP, Malagola C, Pagani J, et al. Rapid maxillary expansion in children with obstructive sleep apnea syndrome: 12 months follow-up. *Sleep Med* 2007; 8: 128–134.
- Villa MP, Bernkopf E, Pagani J, et al. Randomized controlled study of an oral jaw-positioning appliance for the treatment of obstructive sleep apnea in children with malocclusion. *Am J Respir Crit Care Med* 2002; 165: 123–127.
- Pirelli P, Saponara M, Guilleminault C. Rapid maxillary expansion in children with obstructive sleep apnea syndrome. *Sleep* 2004; 27: 761–766.
- Villa MP, Rizzoli A, Miano S, et al. Efficacy of rapid maxillary expansion in children with obstructive sleep apnea syndrome: 36 months of follow-up. *Sleep Breath* 2011; 15: 179–184.
- Guilleminault C, Monteyrol PJ, Huynh NT, et al. Adeno-tonsillectomy and rapid maxillary distraction in pre-pubertal children, a pilot study. *Sleep Breath* 2011; 15: 173–177.
- Bhattacharjee R, Kheirandish-Gozal L, Spruyt K, et al. Adenotonsillectomy outcomes in treatment of obstructive sleep apnea in children: a multicenter retrospective study. *Am J Respir Crit Care Med* 2010; 182: 676–683.
- Capdevila OS, Kheirandish-Gozal L, Dayyat E, et al. Pediatric obstructive sleep apnea: complications, management, and long-term outcomes. *Proc Am Thorac Soc* 2008; 5: 274–282.
- Guilleminault C, Huang YS, Glamann C, et al. Adenotonsillectomy and obstructive sleep apnea in children: a prospective survey. *Otolaryngol Head Neck Surg* 2007; 136: 169–175.